

# Use of Radiesse in Combination With Restylane for Facial Augmentation

Michael S. Godin, MD; Mike V. Majmundar, MD; David S. Chrzanowski, MD; Kelley M. Dodson, MD

**Objectives:** To report the long-term results of 72 consecutive patients treated with Radiesse (BioForm Inc, Franksville, Wis) and 29 patients treated with Radiesse and Restylane (Q-Medical, Uppsala, Sweden) and to share recommendations based on our experience.

**Methods:** A total of 72 patients were treated with Radiesse between October 2003 and December 2004. Of these patients, 29 also received Restylane for facial augmentation. Forty-six Radiesse-treated and 15 Radiesse and Restylane-treated patients completed questionnaires detailing their experience with the procedure, postoperative sequelae, overall satisfaction, and satisfaction at each site treated.

**Results:** On a 10-point scale, the overall satisfaction with Radiesse averaged 7.6, and 30 patients (65%) would recommend this procedure to others. Of the 72 patients, 2

(3%) reported persistent nodules, and both required removal of a small amount of the material. The overall satisfaction with the Radiesse and Restylane-combined treatment averaged 8.1, and 12 patients (79%) would recommend this procedure to others. No patients reported persistent nodules.

**Conclusions:** The use of Radiesse and Restylane in combination is an excellent option for facial enhancement. With long-term experience, complications in the lip area with Radiesse treatment are now avoided with the use of Restylane. In contrast to patients treated with Radiesse alone, the combination treatment group in this study tended to have greater immediate and overall satisfaction scores and was more likely to recommend the combination procedure to others.

*Arch Facial Plast Surg.* 2006;8:92-97

THE QUEST FOR FACIAL ENHANCEMENT has led to many innovative treatments for the improvement of facial rhytids and contour defects. Injectable biofillers can potentially offer facial plastic surgeons a means to address these issues; however, all injectable fillers have certain drawbacks that limit their use. Free fat grafts may survive unevenly and become nodular in appearance over time.<sup>1</sup> Their use is also associated with some degree of donor site morbidity.<sup>2</sup> Collagen requires skin testing for safety and is rapidly degraded by the body.<sup>3</sup> Expanded polytetrafluoroethylene grafts are not generally injectable and require a surgical procedure for placement; they can become infected, necessitating removal, can become visible because of thinning of overlying skin, or can extrude.<sup>4</sup> Solid silicone implants may become displaced owing to the lack of any tissue ingrowth. Liquid silicone may also migrate and has been associated with granuloma formation.<sup>5</sup> The ideal material for implantation would be nonimmunogenic, easily injected, long lasting but not permanent, and similar in feel to its

surroundings.<sup>6</sup> Furthermore, an ideal implant would be readily removable if unsatisfactory placement had occurred.

Radiesse (previously marketed as Radiesse FN by BioForm Inc, Franksville, Wis) is an injectable filler that possesses several of these ideal characteristics. Radiesse consists of spherical particles (25-45  $\mu$ m in diameter) of synthetic calcium hydroxylapatite surrounded by an aqueous gel medium; the gel consists of water, glycerin, and sodium carboxymethylcellulose.

Radiesse has been found to be nontoxic, nonmutagenic, and biocompatible through in vitro and in vivo testing.<sup>7</sup> It is currently approved by the US Food and Drug Administration (FDA) for vocal fold augmentation and reconstruction of maxillofacial defects and as a radiopaque tissue marker. It is also used off-label for bladder incontinence and soft tissue augmentation.<sup>7</sup>

Restylane (Q-Medical, Uppsala, Sweden) is a nonanimal stabilized hyaluronic acid that has become increasingly popular for soft tissue augmentation because of its greater longevity and lower rate of hypersensitivity reactions compared with collagen.<sup>8</sup> It is the first hyaluronic acid

**Author Affiliations:**  
Department of  
Otolaryngology-Head and Neck  
Surgery, Virginia  
Commonwealth University  
Health Systems, Richmond.



product to be approved by the FDA for soft tissue augmentation.

The present study was initiated to assess immediate and long-term as well as overall patient satisfaction with the injection of Radiesse alone and Radiesse and Restylane in combination into the soft tissues of the face. Technical considerations in administration of these materials are also addressed.

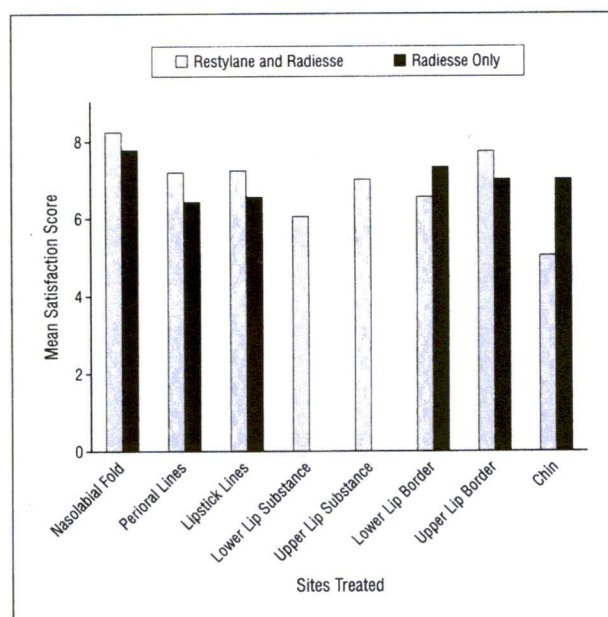
## METHODS

A total of 72 consecutive patients underwent facial augmentation with Radiesse injectable biofiller. Of these patients, 29 requested additional augmentation at sites that had already been injected with Radiesse and were treated with Restylane using a layering technique. Of the 29 patients, 6 were treated concurrently, and the remaining patients were treated, on average, within 103 days of their Radiesse treatment. Prior to treatment, the risks, alternatives, and potential benefits of these materials were discussed with each patient. The off-label status of Radiesse was discussed, and signed informed consent was obtained. Treatment areas for Radiesse included the nasolabial folds, upper and lower lip vermilion borders, "lipstick lines," and perioral lines. Treatment areas for Restylane also included those sites in addition to the upper and lower lip substance. For the purposes of this study, lipstick lines are defined as vertical lines emanating from the vermilion borders of the lips. Perioral lines are all other lines or folds that do not contact the vermilion. These include horizontal lines in the upper and lower lip skin, "smile lines," which appear as parentheses around the oral commissure, and "marionette lines," which usually extend beyond the lipstick line area. The "lip substance" signifies the submucosal space of the lip adjacent to the wet-dry border. Sterile technique was used when injecting Radiesse (using a 1.5-in [3.8-cm], 27-gauge needle) and Restylane (using a 1-in, 30-gauge needle).

For treatment of nasolabial folds and perioral lines, topical 4% lidocaine (Topicaïne; ESBA Laboratories, Jupiter, Fla) was applied and covered with cut strips of household plastic wrap to occlude it for 30 minutes prior to the procedure. For treatment of the lips and lipstick lines, local injection of the infra-orbital and mental nerves was performed using 1% lidocaine without epinephrine. A small amount of local infiltration as well as a midline injection of 0.5 mL into the upper and lower lip mucosa near the gingivolabial sulcus was also performed to block sensation in the midline lip area.

All Radiesse-treated patients were followed up for an average of 15 months (range, 6.5-20 months); all of the Radiesse and Restylane-treated patients were followed up for an average of 11.5 months (range, 8-15 months). Postprocedure sequelae were carefully recorded over several visits. A Nikon D-1 digital SLR camera (Nikon Corp, Tokyo, Japan) with an attached 105-mm Nikkor macro lens (Nikon Corp) was used for photodocumentation in standard views prior to the procedure and at interval follow-up visits after treatment. Following treatment, 46 Radiesse-treated and 15 Radiesse and Restylane-treated patients completed a satisfaction survey.

A 10-point scale was used (1, very poor; 3, poor; 5, fair; 7, good; 9, very good; and 10, excellent) to assess patient satisfaction. Patient responses were then grouped into 4 categories ( $\geq 8$  representing an excellent result; 6-7, a good result; 4-5, a fair result; and  $\leq 3$ , a poor result). The site-specific, immediate, long-term, and overall satisfaction means were calculated. Overall satisfaction encompassed general patient satisfaction over both the immediate and long-term period. Postoperative sequelae such as pain,



**Figure 1.** Mean satisfaction scores per site in patients treated with Radiesse (BioForm Inc, Franksville, Wis) only or with Restylane (Q-Medical, Uppsala, Sweden) and Radiesse. Radiesse was not injected into the upper or lower lip substance; thus, a mean satisfaction score for these sites is not recorded.

downtime after procedure, bruising, and palpable areas of filler were also noted.

## RESULTS

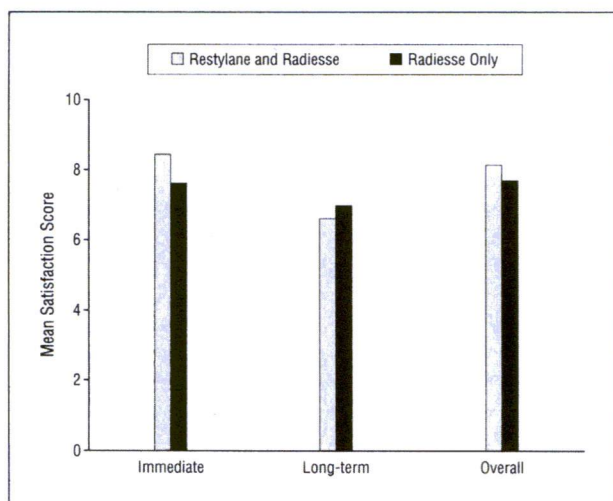
A total of 72 patients (68 women and 4 men) were treated with Radiesse between October 2003 and February 2005. The mean patient age was 54 years (range, 31-78 years). The mean follow-up after treatment was 467 days (range, 198-602 days). Of the 72 Radiesse surveys that were mailed, 46 patients (64%) responded. Patients who were treated within 3 months of their survey were excluded. The mean time from treatment to survey was 318 days (range, 107-455 days). The average amount of Radiesse used was 0.91 mL. One patient received botulinum toxin injections in the upper face, and 4 patients underwent rhytidectomy at the time of treatment.

Of the 72 patients treated with Radiesse, 29 (27 women and 2 men) were also treated with Restylane at similar sites for further facial augmentation (6 patients [21%] were treated concurrently and the remainder were treated on average within 103 days of their Radiesse treatment). The mean patient age was 56 years (range, 38-78 years). The mean follow-up after Restylane treatment was 347 days (range, 235-462 days). Of the 29 combination treatment surveys that were mailed, 15 patients (52%) responded. The mean time from treatment to survey was 196 days (range, 94-297 days). Patients who were treated within 3 months of their survey were excluded. The average amount of Restylane used was 1.1 mL.

### SITE-SPECIFIC SATISFACTION SCORES

**Figure 1** summarizes site-specific satisfaction scores reported from treatment with Radiesse alone and a combination of Radiesse and Restylane.





**Figure 2.** Comparison of the immediate, long-term, and overall mean satisfaction scores of patients treated with Radiesse (BioForm Inc, Franksville, Wis) only vs Restylane (Q-Medical, Uppsala, Sweden) and Radiesse. Overall satisfaction encompasses general patient satisfaction over the short-term and long-term period.

### Radiesse Alone

Of the 46 respondents treated with Radiesse alone, 39 (85%) were treated in the nasolabial fold, 26 of whom provided a mean site-specific satisfaction score of 7.8 out of 10, with 22 patients (85%) reporting excellent (n=16 [62%]) or good (n=6 [23%]) results. Of the 29 patients (63%) treated with Radiesse alone in the upper vermilion border, 22 responded and provided a mean site-specific satisfaction score of 7.0, with 15 (68%) reporting excellent (n=12 [55%]) or good (n=3 [14%]) results. Of the 28 patients (61%) treated with Radiesse in the lower vermilion border, 19 responded and provided a mean site-specific satisfaction score of 7.3, with 15 (79%) reporting excellent (n=11 [58%]) or good (n=4 [21%]) results. Of the 7 patients (15%) who received Radiesse injections into the lipstick lines, 4 responded, providing a mean site-specific satisfaction score of 6.5, with 3 (75%) reporting excellent (n=2 [50%]) or good (n=1 [25%]) results. Of the 27 patients (59%) treated in the perioral region, 16 responded, providing a mean site-specific satisfaction score of 6.4, with 11 (69%) reporting excellent (n=6 [38%]) or good (n=5 [31%]) results. Of the 5 patients (11%) treated with Radiesse in the chin, 3 responded, providing a mean site-specific satisfaction score of 7.0, with all 3 (100%) reporting excellent (n=1 [33%]) or good (n=2 [67%]) results.

### Radiesse and Restylane Combination

In the patients who received combination treatment, Radiesse was used in the nasolabial folds, perioral lines, lipstick lines, and in the upper and lower lip vermilion borders, whereas Restylane was used to complement the effect of Radiesse in these and in the upper and lower lip substance adjacent to the wet-dry border. Of the 15 combination treatment patients surveyed, 12 were treated in the nasolabial fold. Of the 12 patients, 5 provided a mean site-specific satisfaction score of 8.2, with all 5 (100%)

reporting excellent (n=3 [60%]) or good (n=2 [40%]) results. Of the 13 patients treated in the upper vermilion border, 7 responded, providing a mean site-specific satisfaction score of 7.7, with 6 (86%) reporting excellent (n=4 [57%]) or good (n=2 [29%]) results. Of the 6 patients who had their upper lip substance treated, 2 provided a mean site-specific satisfaction score of 7.0, with both (100%) reporting excellent (n=1 [50%]) or good (n=1 [50%]) results. Of the 12 patients treated in the lower vermilion border, 6 provided a mean site-specific satisfaction score of 6.5, with 3 (50%) reporting excellent (n=2 [33%]) or good (n=1 [17%]) results. Of those surveyed, 7 were treated with Restylane in the lower lip substance and 3 provided site-specific satisfaction scores with a mean of 6.0, with 2 (67%) reporting excellent (n=1 [33%]) or good (n=1 [33%]) results. Of the 15 patients who received treatment of lipstick lines, 12 provided a mean site-specific satisfaction score of 7.2, with 7 (78%) reporting excellent (n=5 [56%]) or good (n=2 [22%]) results. In the perioral region, 13 patients (87%) had been treated and 6 patients responded, providing a mean site-specific satisfaction score of 7.2, with 5 (83%) reporting excellent (n=3 [50%]) or good (n=2 [33%]) results. The chin was treated in 3 patients and 1 responded, who provided a site-specific satisfaction score of 5.

### OVERALL, IMMEDIATE, AND LONG-TERM SATISFACTION SCORES

#### Radiesse Alone

The mean overall, immediate, and long-term Radiesse satisfaction scores were 7.6, 7.5, and 6.9 out of 10, respectively (**Figure 2**). Of the 46 patients who responded to the survey, 36 (78%), 38 (83%), and 31 (69%) rated their overall, immediate, and long-term satisfaction with Radiesse as either excellent or good, respectively; 30 (65%) of the 46 respondents would recommend this product to a friend.

#### Radiesse and Restylane Combination

The mean overall, immediate, and long-term satisfaction scores of patients treated with a combination of Radiesse and Restylane were 8.1, 8.4, and 6.5 out of 10, respectively (**Figure 2**). Of the 15 patients who responded to the survey, 13 (86%), 13 (86%), and 10 (69%) rated their overall, immediate, and long-term satisfaction with Radiesse and Restylane combination as either excellent or good, respectively; 12 (79%) of the 15 respondents would recommend this combination to a friend.

Although there was not a clear statistical difference between the 2 groups in this study, patients in the combination treatment group tended to have greater immediate and overall satisfaction scores and were more likely to recommend the combination procedure to others.

### ADVERSE REACTIONS

Most patients, whether treated with Radiesse alone or with a combination of Radiesse and Restylane, experienced mild to no pain during treatment, and only 3 patients (5%)



surveyed did not find local anesthesia helpful. Downtime longer than 24 hours was reported in 8 (17%) of the 46 Radiesse-treated patients and in 2 (13%) of the 15 combination treatment patients; this was mostly related to significant subjective bruising or swelling. In both groups, 3 of 4 patients experienced minor sequelae, which generally resolved quickly. In the Radiesse-only group, bruising was the most reported sequelae, occurring in 21 patients (46%), followed by temporary visible product nodularity, occurring in 15 patients (33%). In the combination treatment group, swelling was the most common sequelae, reported by 7 patients (47%).

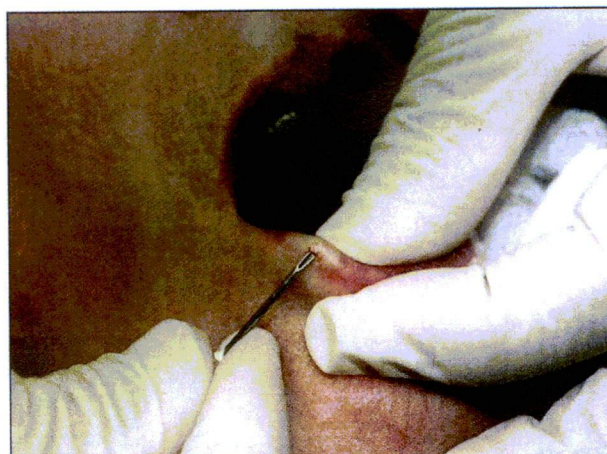
Two patients (3%) developed areas of sustained Radiesse biofiller collections requiring removal. In 1 of these patients, the material was placed in too superficial a location in the area of the right nasolabial fold. The injection was most likely middermal, and the white color of the Radiesse could be seen through the skin for a 6-mm length in the fold. In the second case, too generous an amount was placed into a right lower lip vermillion border, and a 7-mm visible ridge resulted. Removal was accomplished by unroofing the area over the injected material with an 18-gauge needle and teasing out the visible excess (**Figure 3**). In this patient, 3 separate procedures using an open dissection technique were required to remove all of the visible Radiesse material, and the patient has healed well.

#### COMMENT

The overall patient satisfaction score was higher for the combination treatment group than for the Radiesse-only group (8.1 vs 7.6), as was the immediate satisfaction score (8.4 vs 7.5). Although there was not a clear statistical difference between the 2 groups in this study, patients in the combination treatment group tended to have greater immediate and overall satisfaction scores and were more likely to recommend these procedures to others.

Similar to other soft tissue fillers, Radiesse is easily injectable, has a smooth and soft consistency, and can be molded by the physician or even properly instructed patient to reduce lumpiness. It is long-lasting but not permanent. The manufacturer purports the material to persist 1 to 1.5 years in the face, which is a decrease from the 2 to 5 years that was claimed when the material first became available in the United States. Radiesse can be removed under local anesthesia when the effect is more than desired. Refrigeration of the product is not required. In addition, Radiesse gives a 1-to-1 correction that appears to diminish only slightly when swelling has abated.

In contrast to nonstabilized hyaluronic acid, which lasts only days to weeks, nonanimal stabilized hyaluronic acid is an intermediate-term filler lasting 6 to 9 months. Restylane is a single-use material that does not require refrigeration. Restylane has a slightly smoother and softer consistency compared with Radiesse. When explaining the appearance to patients, we sometimes liken Radiesse to a cake and Restylane to the icing on the cake. Restylane helps, in our experience, to complement Radiesse in the desired rejuvenating effect where needed. For ex-



**Figure 3.** Technique of removing Radiesse (BioForm Inc, Franksville, Wis) using an 18-gauge needle and local anesthesia. In this example, the visible nodule was on the right lower lip vermillion border.

ample, Radiesse can be used in the subdermal plane to efface a deep nasolabial fold, and Restylane may be layered in the middermis above it to soften the line etched in the skin at the depths of the fold.

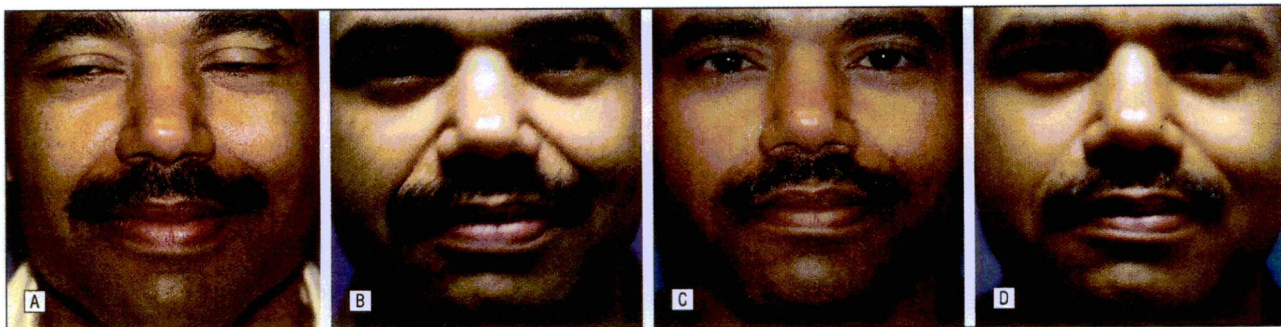
For patients treated with Radiesse alone, the nasolabial fold had the highest site-specific satisfaction score at 7.8. Patients treated with both Radiesse and Restylane had an even higher site-specific satisfaction score for the nasolabial fold at 8.2.

Our data are consistent with the other few clinical reports that have been published on Radiesse. Tzikas<sup>6</sup> noted an 88% good or excellent overall patient satisfaction rate with Radiesse. Our rate of 79% of patients with good or excellent overall outcome confirms patient satisfaction with this material. Likewise, similar rates of transient and persistent nodularity as well as necessity for removal of Radiesse have been found in other studies. For example, Tzikas<sup>6</sup> reported that 48% of his patients exhibited minimal or moderate nodularity within 4 weeks of treatment, 8% of patients complained of persistent subcutaneous nodules, and 4% required intervention. Sklar and White<sup>9</sup> noted a 6% rate of delayed subcutaneous nodules. All of their patients improved with the use of intralesional steroids. The same authors noted higher rates of nodularity with Radiesse use in the lip, with 36% of patients reporting mild nodularity and 8% describing their nodules as moderate.<sup>9</sup> All of these results are in line with those of our study, wherein 33% of patients developed transient nodularity and 3% developed persistent nodules that required treatment. We believe that both of our complications (persistent nodules) could have been avoided with proper placement in the plane immediately deep to the dermis and proper site selection as described in the following section.

#### CLINICAL GUIDELINES

The following recommendations for the use of Radiesse and Restylane are based on our experience with these materials. While some of these guidelines are not specific to any one filler material, all have served us well in treating our patients.





**Figure 4.** Patient photographs prior to nasolabial fold enhancement with Radiesse (BioForm Inc, Franksville, Wis) (A and B) and 1 year after (C and D). In B and D, flash photography was not used to permit better visualization of facial contours.

### PHOTOGRAPHY

Changes in facial contour, especially subtle ones, are notoriously difficult to demonstrate photographically. Flash photography tends to wash out the shadows and highlights that signal such changes. At least 1 view should be taken without use of a flash before and after the procedure. Such photographs often display contour changes more dramatically compared with images taken using a flash (**Figure 4**).

### ANESTHESIA

Topical anesthesia makes injection of the biofiller tolerable when treating the nasolabial folds and perioral lines. However, with treatment of the lip and lipstick lines, we recommend transoral injection of 1% lidocaine without epinephrine to block the infraorbital and mental nerves bilaterally. A midline injection in the upper and lower lip as well as a limited amount of local infiltration is often necessary to achieve complete anesthesia. The absence of epinephrine decreases the duration of postoperative numbness and the possibility of tachycardia and hypertension during the procedure.

### SITE SELECTION

Given its relative thickness and white color, Radiesse is not an appropriate material to place in the superficial or middle dermis. Furthermore, areas where skin is thinnest should, in our opinion, be avoided. The nasolabial folds, chin, cheeks, and even the vermillion border area are thick enough in most patients to conceal the material. If Radiesse is used at the vermillion border, great care must be taken to administer a thin, continuous strand to avoid nodules. We typically use a 1.75-in (4.45-cm), 27-gauge needle and inject 0.1 mL into each lip quadrant and have had no complaints of nodularity using this conservative technique. When an increase in lip volume or improvement of the lipstick lines is desired, we use Restylane.

### ADJUSTMENT OF MATERIAL

Radiesse and Restylane can be manipulated to change its position or decrease nodularity immediately after it has been injected. We commonly use a precise pinching technique,

using one gloved finger in the mouth and one on the skin to palpate the filler and compress the material into the optimal position. The physician can have the patient observe this process using a hand mirror and instruct him or her to do the same gently at home, should a visible nodule occur. The patient should allow a day to go by for the abatement of swelling before attempting to do this. It is also important to instruct the patient that only visible nodules should be massaged, as it is normal to palpate areas of the filler material with either the fingers or the tongue in the first few days after its administration. Radiesse becomes less palpable approximately 3 days after injection, so only nodules that are seen should be manipulated.

### PRODUCT STORAGE AND READMINISTRATION

Sterile technique must be used in every phase of Radiesse administration, including recapping of the syringe and storing of the material in the office. The current recommendation from the manufacturer is that the Radiesse that is unused at the first treatment may be stored for up to 3 months for that patient before it must be discarded. It is important that no visible air be present in the capped syringe to prevent premature hardening of the material. The company provides 3 labels identifying the lot number of the Radiesse syringe in use so that the first and second procedures can be documented in the patient's chart alongside self-adhesive labels. The third label is affixed to a mailing card, which reports data concerning the patient and procedure to the manufacturer. Restylane is classified as a single-use material by the manufacturer, so left-over filler should not be saved.

### CONCLUSIONS

Radiesse and Restylane are reliable, well-tolerated filler materials that create volume where desired in the face. Complications that occurred were infrequent and were related to the technique or site of application rather than to antigenicity. With long-term experience and follow-up, complications in the lip area with Radiesse injection are now avoided with the use of Restylane. Patients receiving these biofillers were generally pleased with the results of the procedure. Patients in the combination treatment group tended to have greater immediate and overall satisfaction scores and were more likely to recommend these procedures to



others. The biocompatibility and long-term effects of Radiesse make it an attractive filler material. In addition, the use of Restylane in certain injection sites complements Radiesse in the desired rejuvenating effect.

Accepted for Publication: November 11, 2005.

Correspondence: Michael S. Godin, MD, 410 Libbie Ave, Richmond, VA 23226 (msgmd@earthlink.net).

Previous Presentation: This study was presented at the Fall Meeting of the American Academy of Facial Plastic and Reconstructive Surgery; September 22, 2005; Los Angeles, Calif.

## REFERENCES

1. Pinski KS, Coleman WP. Microlipoinjection and autologous collagen. *Dermatol Clin*. 1995;13:339-351.
2. Chajchir A, Benzaquen I. Liposuction fat grafts in face wrinkles and hemifacial atrophy. *Aesthetic Plast Surg*. 1986;10:115-117.
3. Cooperman LS, Mackinnon V, Bechler G, et al. Injectable collagen: a six-year clinical investigation. *Aesthetic Plast Surg*. 1985;9:145-151.
4. Wall SJ, Adamson PA, Bailey D, et al. Patient satisfaction with expanded polytetrafluoroethylene (Softform) implants to the perioral region. *Arch Facial Plast Surg*. 2003;5:320-324.
5. Lemperle G. PMMA microspheres (Artecoll) for skin and soft tissue augmentation: clinical investigations. *Plast Reconstr Surg*. 1995;96:627-634.
6. Tzikas TL. Evaluation of the Radiance FN soft tissue filler for facial soft tissue augmentation. *Arch Facial Plast Surg*. 2004;6:234-239.
7. Hubbard W. 36-Month biocompatibility study of calcium hydroxylapatite microspheres in 24 female dogs. Bioform Inc Web site. Available at: <http://www.bioforminc.com/us/radiesse/Biocompatibility.htm>. Accessed December 15, 2004.
8. Bellew SG, Carroll KC, Weiss MA, Weiss RA. Sterility of stored nonanimal, stabilized hyaluronic acid gel syringes after patient injection. *J Am Acad Dermatol*. 2005; 52:988-990.
9. Sklar JA, White S. Radiance FN: a new soft tissue filler. *Dermatol Surg*. 2004;30: 764-768.

## Announcement

### Clinical Trial Registration

**I**n concert with the International Committee of Medical Journal Editors (ICMJE), *Archives of Facial Plastic Surgery* will require, as a condition of consideration for publication, registration of clinical trials in a public trials registry (such as <http://ClinicalTrials.gov> or <http://controlled-trials.com>). Trials must be registered at or before the onset of patient enrollment. This policy applies to any clinical trial starting enrollment after March 1, 2006. For trials that began enrollment before this date, registration will be required by June 1, 2006. The trial registration number should be supplied at the time of submission.

For details about this new policy see the editorials by DeAngelis et al in the September 8, 2004 (2004;292: 1363-1364), and June 15, 2005 (2005;293:2927-2929), issues of *JAMA*.